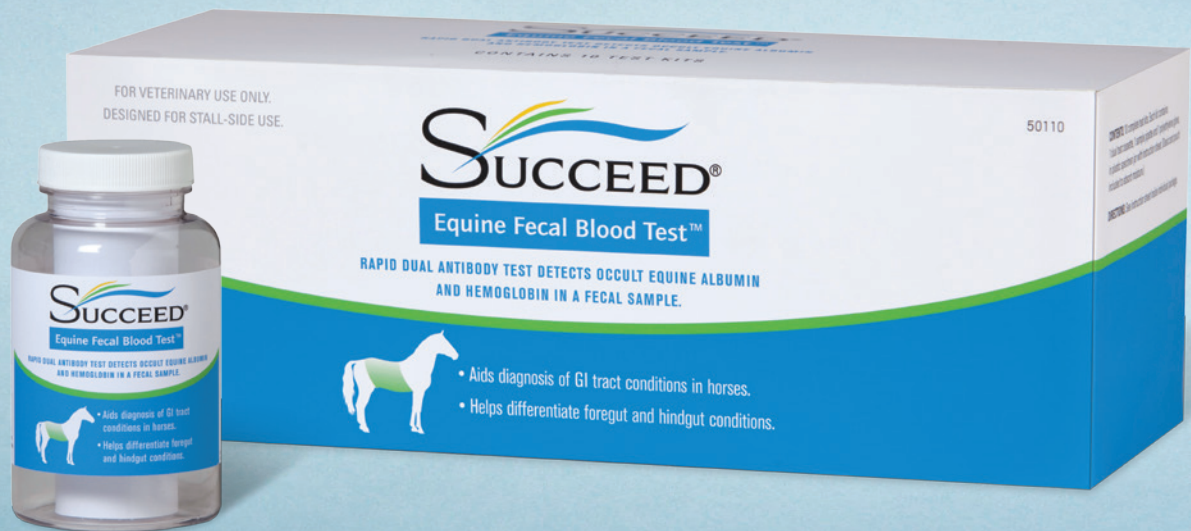

THE DEVELOPMENT OF A FECAL ANTIBODY TEST TO SUPPORT THE DIFFERENTIAL DIAGNOSIS OF EQUINE GASTROINTESTINAL DISORDERS

A REVIEW OF THE RESEARCH
AND DEVELOPMENT BEHIND THE
SUCCEED® EQUINE FECAL BLOOD TEST™



SUCCEED®
Equine Fecal Blood Test™



Over the course of ten years, we have observed a high rate of gastric and colonic ulcers in more than 1,100 horses at abattoirs in the United States and Canada. Throughout, we have tested several technologies that endeavor to detect these lesions using a fecal sample. We now report on an improved antibody test kit.

The SUCCEED® Equine Fecal Blood Test™ is a highly accurate and sensitive diagnostic aid that can help practitioners differentiate gastric from colonic sources of bleeding that reflect ulcers, inflammation and related digestive tract pathologies. The kit is a two-part field test that is easy to employ and provides results in minutes.

ULCER INCIDENCE IN PERFORMANCE HORSES

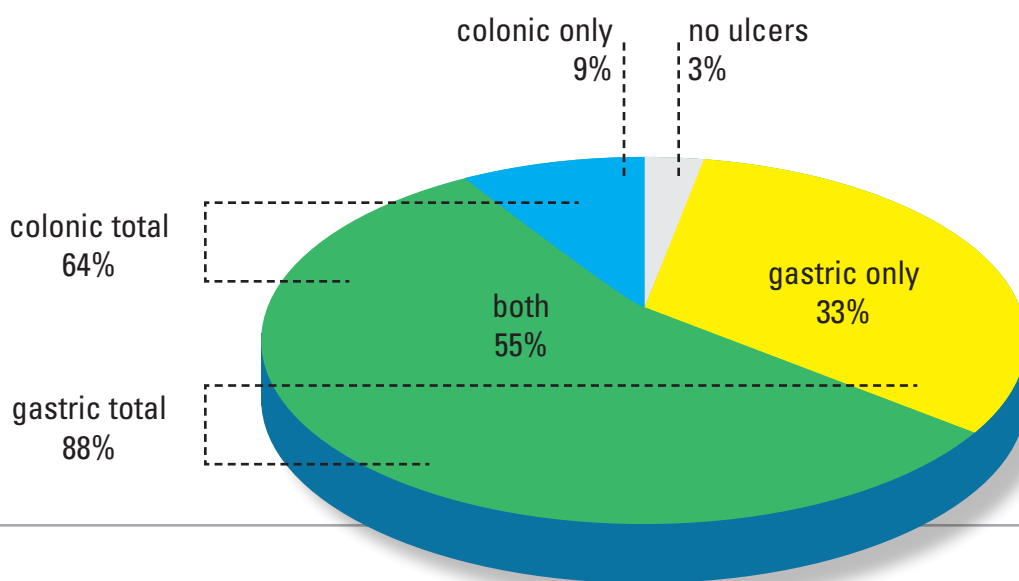


Figure 1: A 2003 study at a Texas abattoir found that only 3% of performance horses had no ulceration, and that a majority (55%) had both colonic and gastric lesions.

Most veterinarians are familiar with Equine Gastric Ulcer Syndrome (EGUS), which manifests primarily as lesions in the distal esophagus, the squamous area of the stomach and the proximal duodenum.^{1,2,3} Gastric ulcers can be visualized with a three-meter endoscope, but the gastric area that is home to EGUS represents less than 10% of the equine GI tract.

In 2003, Freedom Health conducted a necroscopic study of 180 performance horses to gather data on the incidence of GI ulcers, and to correlate these gross observations to a guaiac-based fecal blood test (gFBT). We anticipated a significant level of gastric ulceration, but also predicted that colonic ulcers would be present as well. This was based on the rates of sub-clinical anemia or intestinal inflammation that we felt were negatively impacting the performance of show and race horses in practice, even in cases where gastric ulcers were not detected.

The resulting analysis (Pellegrini, 2005) revealed that 87% had gastric ulcers and 63% had colonic ulcers, with an overall ulceration rate of 97%.⁴ In this study, we correlated the gFBT to the gross examination of intestinal tissue with the hope that such a fecal test might aid the diagnosis of these conditions. Overall, the gFBT proved to be specific and significant for the presence of an ulcer, but the existence of false negatives limited the overall accuracy of the test to 65%, roughly comparable to human outcomes with such a test.

Our observations clearly demonstrated that lesions and inflammation within the equine digestive tract are not confined to the stomach. We saw several instances of right dorsal colitis, a known problem with horses taking NSAIDs. But in addition, we saw ulcers in other quadrants of the colon. This was unexpected, because colonic ulceration in these other quadrants was not

noted in the literature. In this study, and in several additional studies over the following ten years, we have found large cysts, focal pinpoint ulcers, widely disseminated ulcers, petechiation and ecchymoses in all quadrants of the colon.

Introducing the **SUCCEED Equine Fecal Blood Test**

Over the ten-year period from 2003 to 2013, we performed 1,122 equine necropsies in abattoirs in United States and Canada and consistently found lesions in both the stomach and the colon. As well as basic research into the frequency and severity of GI inflammation, we wanted to know if we could create a stall-side fecal test to detect and hopefully differentiate these conditions.

Equine digestion is dominated by hindgut action where ulcers are difficult to observe. Colonoscopies are impractical due to the difficulty of evacuating the equine colon without endangering the health of the horse. As a consequence, most equine vets are not familiar with colonic ulcers. But as we have shown, colitis and inflammation are common and can adversely affect digestive health, resulting in pain, discomfort and impaired performance. The ability to accurately diagnose colitis, and differentiate it from gastritis, is important to determine the proper treatment. These issues may reflect any number of underlying pathologies and, untreated, can lead to anemia, laminitis, colic and even death.⁵

To better quantify this hidden danger, we designed and tested several diagnostic fecal test kits and have conducted several calibration studies over the years. Here we describe our latest field test that detects and potentially differentiates colitis and gastritis.



Figure 2: A grade 3 gastric ulcer with major erosion.

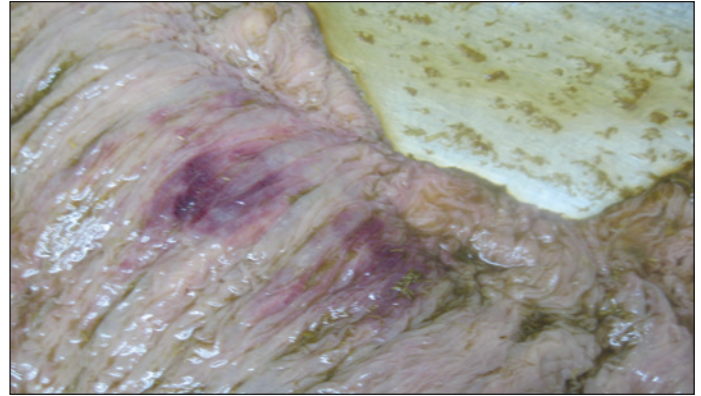


Figure 4: Right-dorsal colitis with a nodule (center).

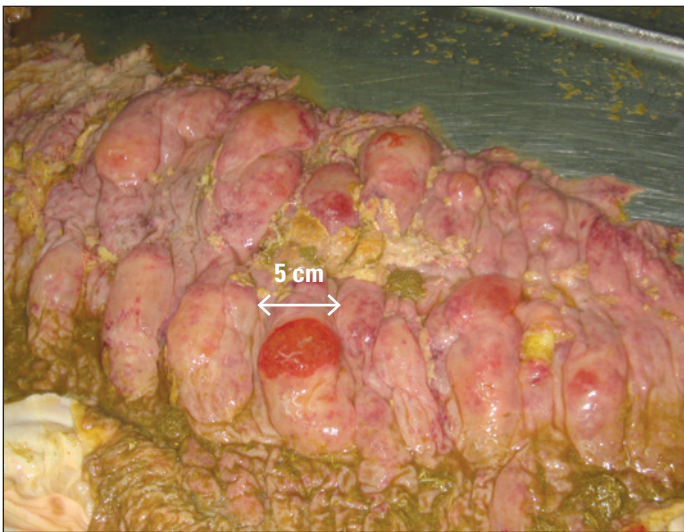


Figure 3: A grade 3 disseminated colonic ulcer with a large lesion.

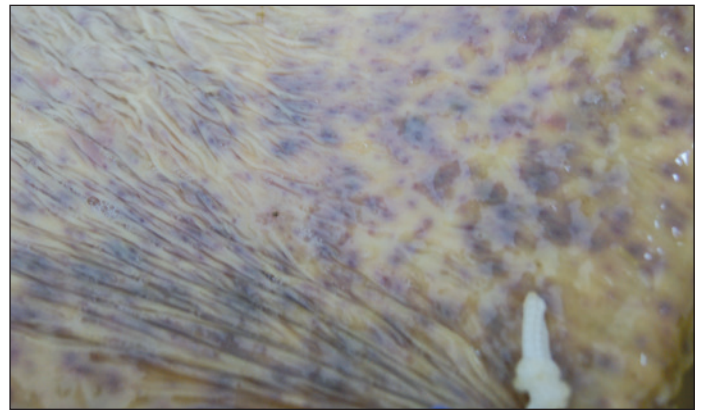


Figure 5: A severe ecchymosis of the left ventral colon.

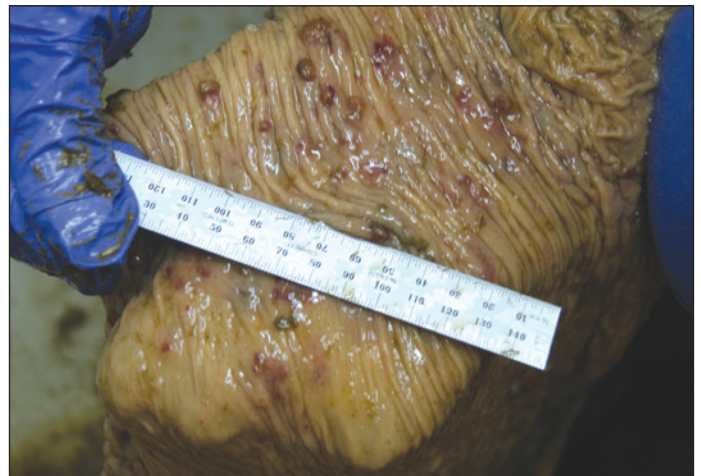


Figure 6: A grade 2 ulcer in the left ventral colon.

Analysis of a Guaiac Test

Our first test used guaiac, a substance that turns blue in the presence of blood and hydrogen peroxide. In all of our necropsic studies, a fecal sample was collected from each horse prior to euthanasia. For the necropsy, the digestive tract was removed and the stomach and colon were tied off for separate examination and then hosed down. Gastric ulcers were noted and graded according to the Practitioner's Simplified Scoring System⁶ on a scale from 0 to 3:

- 0 Intact mucosal epithelium (can have mild reddening and/or mild hyperkeratosis)
- 1 Small single or small multifocal lesion
- 2 Large single or large multifocal lesions or extensive superficial lesions
- 3 Extensive (often coalescing) lesions with areas of apparent deep ulceration

We adopted the same numbering system for colonic ulcers. The scoring system does not explicitly reference bleeding, but our observations have led us to correlate ulcers of grade 2 or higher with the production of whole-blood. Grade 1 ulcers, while not bleeding per se, may be associated with seeping of albumin at the point of injury. The guaiac test was quite specific, but not sensitive enough for our purposes.

Designing an Antibody Test

To improve on the sensitivity of the guaiac test, we turned to the exacting technology of antibody binding, specifically lateral-flow immunoassays. These tests are easy to use in the field, yet still provide the high sensitivity and precision required to detect small quantities of blood products in fecal matter.

To detect and potentially localize equine ulcers, we undertook an analysis of two potential marker proteins found in blood that we hoped could distinguish foregut from hindgut lesions: albumin and hemoglobin. In an experiment conducted with researchers from Island Whirl Equine Colic Research Laboratory at the University of Florida, equine blood was introduced through a gastric cannula to two experimental horses and fecal samples were then taken periodically for the subsequent 18 hours.

Albumin is known to be degraded by enzymes such as pepsin and trypsin in the stomach and duodenum. As a consequence, we expected that any albumin detected in fecal matter must emanate from a hindgut lesion caudal to the duodenum. The study also looked at hemoglobin, which our previous guaiac research had shown can survive both gastric and colonic degradation. Taken together, we realized that detection of these two proteins could provide a novel technique for helping to distinguish these two disjoint areas of inflammation.

These two protein markers were analyzed using an Enzyme-Linked ImmunoSorbent Assay (ELISA). When the results were plotted, we saw that the levels of hemoglobin peaked and then slowly fell over the 18-hour period as expected, while albumin levels remained consistently low due to gastric digestion of the albumin in the injected blood. This demonstrated the utility of these two markers as differential diagnostics. Hemoglobin is a marker for ulcers of grade two and higher, in both fore- and hindgut, while albumin indicates an ulcer in the hindgut only.

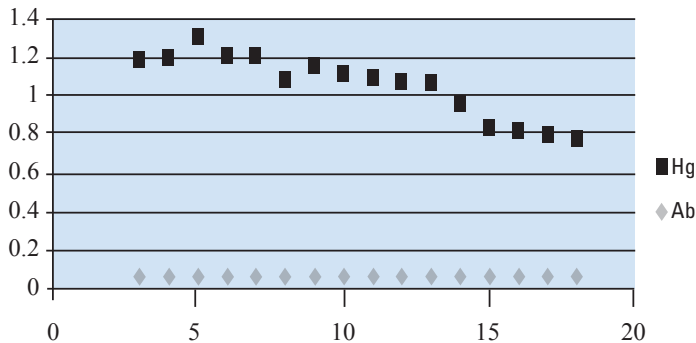


Figure 7: OD₄₅₀ results from an averaged ELISA time-course assay on two horses over an 18-hour period. Note the slow decay of detected hemoglobin and the consistently low levels of albumin.

The following table illustrates the use of hemoglobin and albumin as differential diagnostics:

		Albumin Test (Test A)	
		Negative	Positive
Hemoglobin Test (Test H)	Negative	No GI tract blood components detected. Compromised basement membrane possible in foregut.	GI tract issue detected in hindgut. Compromised basement membrane possible in foregut.
	Positive	Active vascular bleeding in foregut.	GI tract issue detected in hindgut. Active vascular bleeding possible in foregut, hindgut or both.

Creating the Antibody Test

We next set out to determine useful diagnostic levels of these two blood components in compromised GI tissue. Based on the albumin and hemoglobin experiments at Island Whirl, we designed an immunoassay field kit using purified antibodies against albumin and hemoglobin. To prepare the kit, a peptide sequence unique to each equine protein was chosen and synthesized in the lab, further conjugated to enhance immunogenicity, and then injected into rabbits. At two and three months, the rabbits were given booster injections of the peptide sequence to further enhance their immune reaction and maximize antibody production. At the conclusion of three months on the protocol, bleeds were taken from each rabbit, serum was separated from the blood, and all the serum samples were pooled.⁷

Antibodies were then purified using an affinity column containing the original peptide sequence, ensuring that only antibodies to the chosen sequence were in the final antibody preparations.

These proteins have peptide sequences that are uniquely equine, and thus are only present in the equine digestive tract from either ingested equine blood (e.g. from the lungs) or from bleeding occurring at some point in the digestive tract.

The test has one antibody calibrated to detect above-baseline albumin and another for hemoglobin. A couple of drops of diluted fecal matter are placed in each well and after a few minutes, the presence of albumin and hemoglobin are indicated and a diagnosis can be made on the spot.

Calibrating the Antibody Test

We have endeavored to improve the test, in particular to prevent flooding at high blood levels. Each new iteration of the antibody kit has been tested with additional necropsies. These tests were carried out using a protocol similar to the original guaiac studies: upon euthanasia, fecal balls were collected and tested, and these results were then correlated to the visual observations of the horse GI tract. These studies were run blind; the grading of the tests was independent of the bowel dissection. The results of the antibody tests were later correlated to the anatomical observations to check their accuracy and positive predictive value.

For hemoglobin, the antibody test was correlated to the overall level of observed GI ulceration, where the positive gastric and colonic cutoff was set to grade 2 and above (where the ulcer is producing whole blood and, thus, hemoglobin is likely to be present). In our tests, the kits have improved in accuracy over time, going from about 75% to over 80%. Sensitivity is excellent, as antibodies can be made highly responsive. The positive predictive value, which is an indicator of how likely a horse is to have an ulcer given a positive result, has always been good, rising with each test kit formulation from around 80% to over 85%.

For albumin, the antibody test was correlated exclusively to the level of observed colonic ulceration, where the cutoff was set to grade 1 and above (where albumin is likely to be present). As with the hemoglobin tests, these have continually improved in accuracy as we have better understood the normal baseline rate of albumin loss in the hindgut.

Due to the nature of antibody chemistry, the test is generally very sensitive, leading to a low number of false positives. That has led to good correlations, especially on metrics such as accuracy, specificity and positive predictive value.

The most recent necropsy study was completed in October, 2011, with 178 horses. In this study we evaluated the version of the test in production at the time, with the following results:

	positive predictive value	negative predictive value	p-value
Albumin (predictive for colonic ulcers)	95.4%	75.0%	.04
Hemoglobin (predictive for gastric or colonic ulcers)	96.9%	57.9%	.03

The positive predictive value of both the albumin and hemoglobin tests is high: a positive result predicts a high likelihood that a colonic or gastric ulcer is present. The negative value for hemoglobin appears less predictive in this study due to a low number of negatives in this particular cohort. (The albumin portion of the current iteration of the test kit has the lower visible limit raised to 2PPM, compared to 1PPM in the version evaluated in 2011.)

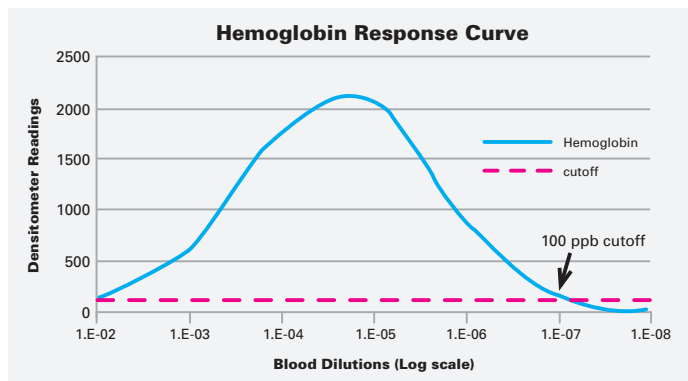
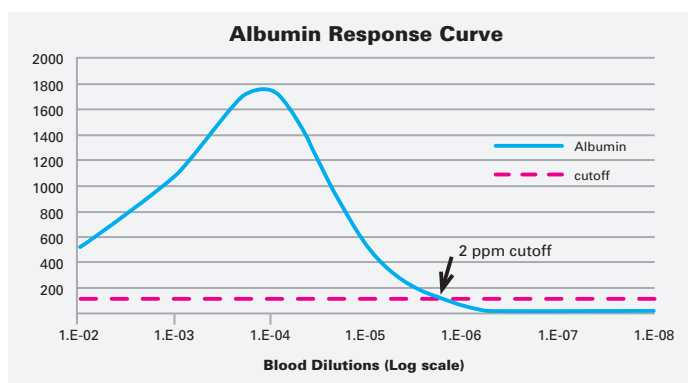
While the antibody test is reliable and accurate, it is important to remember that horses themselves are somewhat variable. Normal horse blood can have from 11-19 g/dL of hemoglobin and 2.4-4.2 g/dL of albumin, but intermittent bleeding and variations in fecal output can also affect blood concentrations. These measures may change over time for any given subject, so blood volumes cannot be rigorously computed from a single measurement. As a result, repeated testing over an extended period can help to build a better picture of actual blood loss.

In Vitro Response Curves

The accuracy of the SUCCEED FBT is validated by serial dilutions of horse blood, typically in powers of ten.

There are two wells in the kit, one to detect albumin and one for hemoglobin. In water, the sensitivity of the test is 2 parts per million (ppm) for albumin and 0.1 ppm for hemoglobin, based on whole blood equivalents. When either protein exceeds its cutoff value, a red line shows up in its window.

The graph goes from low to higher dilutions (lower concentrations) as you move to the right. The vertical axis lists densitometer readings; the dashed line represents the densitometer cutoff below which the test line is no longer visible to the naked eye. The cutoff for albumin is where the curve intersects the dashed line, at 2 ppm. For hemoglobin the cutoff is set to 100 ppb.



The SUCCEED FBT lets you conduct a simple test on a horse stall-side, without invasive or costly diagnostic procedures or referrals. The test provides a quick objective measure of possible foregut and hindgut lesions and related conditions without relying solely on symptomology and other subjective inputs. Armed with this information, you can include or exclude various hypotheses about the health of the horse.

The two-part diagnostic can be performed in a few minutes with no extra equipment – a fecal sample and approximately 3 oz. of clean tap water, along with the contents of a single kit, are all that is required to test one horse. The results are easy to read directly from the window of the rapid-test kit, and appear in minutes.

Because the test can be performed in minutes, it is possible to test a number of horses in a barn or other boarding environment in the course of a typical client visit. Given the ease and affordability of the SUCCEED FBT, practitioners can easily test all of their clients' horses on a consistent schedule. Regular testing is especially important for performance horses, or whenever the care, feeding and general husbandry are less than ideal for digestive health, including intermittent feeding, high-grain diets, stall confinement or trailering.

Using the Antibody Test

As constituted, the Albumin/Hemoglobin FBT is useful for detecting GI lesions and for possibly differentiating between gastritis and colitis. It can be used in conjunction with the horse's history to examine possible consequences of NSAID usage, including RDC. It can also be used to test for Protein Losing Enteropathy (PLE); the albumin part of the test is a sensitive indicator of albumin loss, and is set high enough to ignore normal baseline levels.

But the test has greater utility as a long-term, general-purpose diagnostic for inclusion in your armamentarium. We use the kit on a regular schedule for our test horses to ensure that our functional feed products are safe and efficacious. Other veterinarians use the kit regularly to:

- Establish baselines for new patients
- Monitor general wellness
- Confirm a preliminary diagnosis of GI problems
- Establish a treatment based on any GI differential discovered
- Assess treatment progress
- Add important findings to a pre-purchase exam
- Monitor internal bleeding for colic surgery patients


Testing a client's horses, even those assumed to be in good digestive health, can provide an opportunity for the veterinarian to educate their clients about these hidden GI issues. It can help you to provide a proper physiological context for many of the performance or behavioral issues horse owners and trainers face regularly, but which are often attributed to poor training or the horse's individual attitude or ability.

References

- ¹ Andrews FM, Bernard WV, Byars TD (1999), "Recommendations for the diagnosis and treatment of equine gastric ulcer syndrome (EGUS)", *Equine Vet. Educ.*; 1: pp. 122–134.
- ² McClure SR, Glickman LT, Glickman NW (1999), "Prevalence of gastric ulcers in show horses", *J Am Vet Med Assoc*; 215: pp. 1130–1133.
- ³ Michell RD (2001), "Prevalence of gastric ulcers in hunter/jumper and dressage horses evaluated for poor performance", in *Proceedings. Annual Meeting of the Association of Equine Sports Medicine 2001*; pp. 74–77.
- ⁴ Pellegrini FL (2005), "Results of a large-scale necroscopic study of equine colonic ulcers", *J Equine Vet Sci*; 25 (3): pp. 113–117.
- ⁵ Murray MJ (1994), "Gastric ulcers in adult horses", *Comp Cont Educ Pract Vet*; 16: pp. 792–794, 797.
- ⁶ Andrews FM, Sifferman RL, Bernard W, Hughes FE, Holste JE, Daurio CP, Alva R, Cox JL (1999), "Efficacy of omeprazole paste in the treatment and prevention of gastric ulcers in horses", *Equine Vet. J.*; 31: pp. 81–86.
- ⁷ Barrows GH, Burton RM, Jarett DD, Russell GG, Alfor MD, Songster CL (1978), "Immunochemical detection of human blood in feces", *Am J of Clin Path*; 69 (3): pp. 342–346.



The SUCCEED Equine Fecal Blood Test is available exclusively to veterinarians through major veterinary supply distributors in the U.S and Canada.:



FREEDOM HEALTH, LLC
65 Aurora Industrial Parkway
Aurora, OH 44202
877-734-6558
www.SucceedFBT.com

